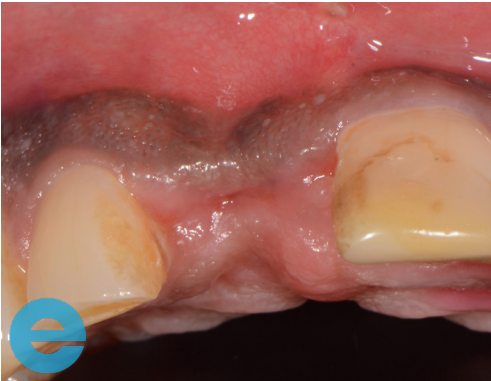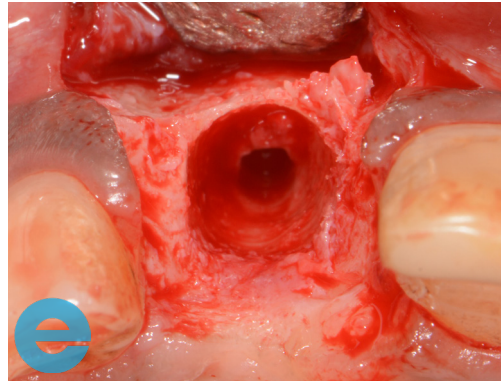


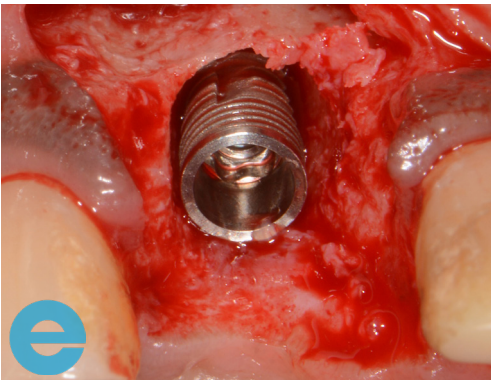
# ANTERIOR RIDGE CASE STUDY



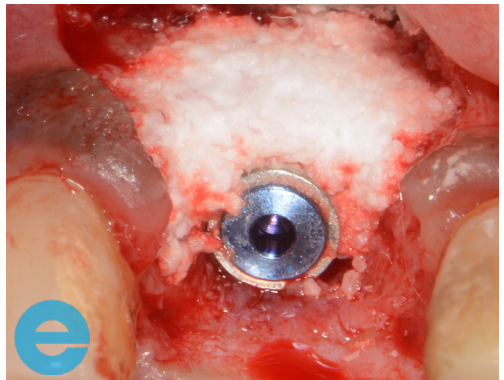
1. Case at 4 weeks post extraction, profile loss.



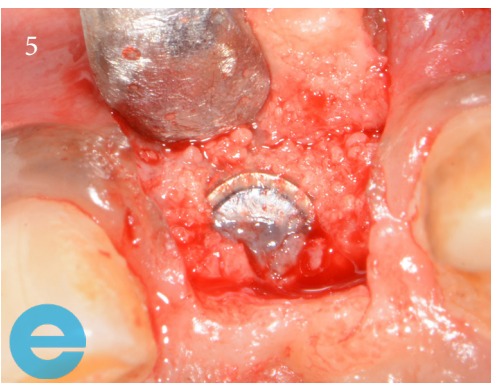2. Bone loss and site cleaned showing pilot drill site.



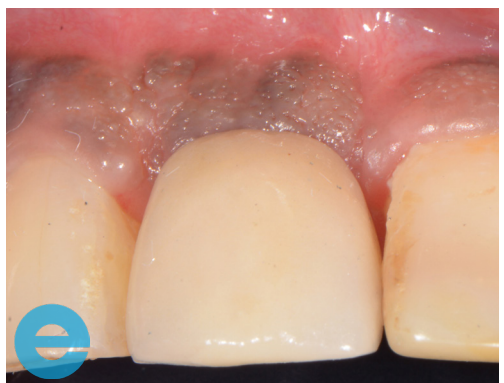3. Placement of Implant to the correct level.



4. Grafted with EthOss®.



5. New bone at 12 weeks.



6. Restored 3 months.



# GROW STRONGER

## USEFUL RESOURCES

### RECOMMENDED CLINICAL PROTOCOL

*Clinical study showcasing recommended clinical protocol for EthOss*

Download

### SURGICAL GUIDELINES

*The official recommended guide on how to use EthOss*

Download

### HOW TO MIX ETHOSS

*Explainer video*

Watch